

Case Series

The Effect of Piezoelectric Use on Open Sinus Lift Perforation: A Retrospective Evaluation of 56 Consecutively Treated Cases From Private Practices

Nicholas J. Toscano,* Dan Holtzclaw,[†] and Paul S. Rosen[‡]

Background: The lateral window approach to maxillary sinus augmentation is a well-accepted treatment option in implant dentistry. The most frequent complication reported with traditional techniques has been the perforation of the Schneiderian membrane, with perforation rates ranging from 11% to 56%. The purpose of this retrospective, consecutive case series from two private practices was to report on the rate of Schneiderian membrane perforations and arterial lacerations when a piezoelectric surgical unit was used in conjunction with hand instrumentation to perform lateral window sinus elevations.

Methods: Clinical data (Schneiderian membrane perforation, Underwood septa, and laceration of the lateral arterial blood supply to the maxillary sinus) were obtained retrospectively from two private practices and pooled for analysis. The information was collated after an exhaustive chart review. Fifty-six consecutively treated lateral window sinus lifts were performed on 50 partially or completely edentate patients.

Results: Zero perforations of the Schneiderian membrane occurred during the piezoelectric preparation of the lateral antrostomies, whereas two perforations were noted during subsequent membrane elevations using hand instrumentation. In both instances, membrane perforations were associated with sinus septa. The overall sinus perforation rate was 3.6%. Arterial branches of the posterior superior alveolar artery were encountered in 35 cases, and there were zero instances of arterial laceration.

Conclusions: This retrospective case series from clinical private practices confirmed that a lateral window approach to sinus elevation incorporating piezoelectric technology in conjunction with hand instrumentation was an effective means to achieve sinus elevation while minimizing the potential for intraoperative complications. Further prospective and randomized controlled studies are warranted to qualify these observations. J Periodontol 2010;81:167-171.

KEY WORDS

Alveolar ridge augmentation; bone transplantation; complications; dental implants; maxillary sinus; ultrasonic therapy.

* Private practice, Washington, DC.

[†] Currently, private practice, Austin, TX.

[‡] Private practice, Yardley, PA.

Endosseous dental implant surgery in the posterior maxilla requires the consideration of multiple factors, especially those of anatomic origin.^{1,2} Due to the reduced bone quality of the posterior maxilla, edentulism in this sextant often results in a resorbed osseous structure and a pneumatized maxillary sinus.³ When <5 mm of residual bone remains between the alveolar crest and the maxillary sinus, the traditional treatment option of choice prior to implant placement is subantral augmentation, more commonly known as the lateral window sinus lift.^{4,5} This approach to increasing bone available for placing implants uses a “window” in the lateral bony wall of the maxillary sinus to gain access to the underlying Schneiderian membrane.⁶ Although implant survival rates associated with this procedure routinely exceed 90%,^{7,8} the lateral window sinus lift remains a technique-sensitive procedure due to the high risk of Schneiderian membrane perforation and hemorrhagic complications, the latter of which is associated with the inadvertent laceration of the intraosseous arterial supply to this region.^{9,10}

The recent incorporation of piezoelectric technology when performing a lateral window elevation is one way to potentially reduce or eliminate many of the complications associated with this procedure.¹¹⁻¹⁶ The purpose of this retrospective, consecutive case series from two private practices was to report on the complications of Schneiderian membrane perforations and arterial lacerations when a piezoelectric surgical unit was used in conjunction with hand instrumentation when performing lateral window sinus lifts.

MATERIALS AND METHODS

Clinical data (Schneiderian membrane perforation, laceration of the lateral arterial blood supply, and the presence of Underwood septa) were obtained retrospectively from two private practices (Yardley, Pennsylvania and Washington, DC) and pooled for analysis. There were 56 consecutively treated lateral window open sinus lifts performed on 50 partially or completely edentate patients (32 males and 18 females, aged 22 to 68 years) with a piezoelectric surgery unit.[§] All patients required a maxillary sinus augmentation to facilitate the placement of endosseous dental implants. Patients were treated under local anesthesia using articaine 4% with 1:100,000 epinephrine. After elevation of a full-thickness flap that was initiated slightly palatal to the crest of the ridge, all cases had their lateral antrostomies created by outlining an island of bone or completely removing the entire lateral aspect of the window (Fig. 1) using the piezoelectric unit according to the manufacturer's instructions. Where septa were present, the window was outlined to minimize their impact (Fig. 2), or in cases where the septum appeared to be rather thick,

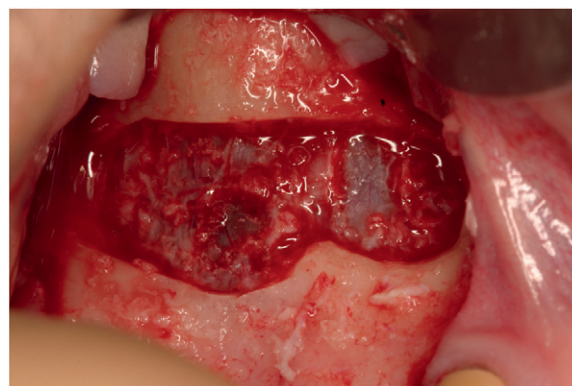


Figure 1.

Sinus window was created by a complete osteotomy, removing the entire lateral bony aspect using piezoelectric inserts.

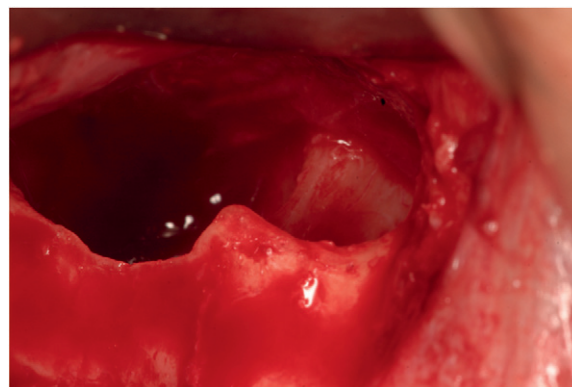
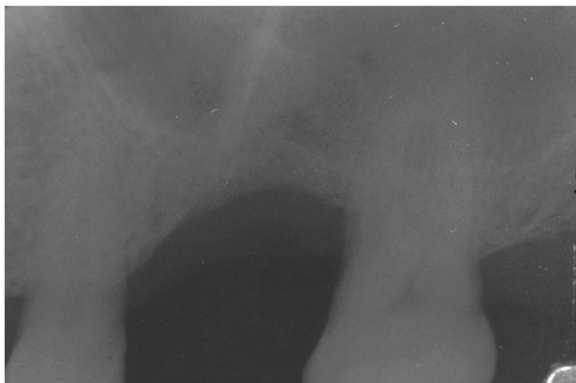

Figure 2.

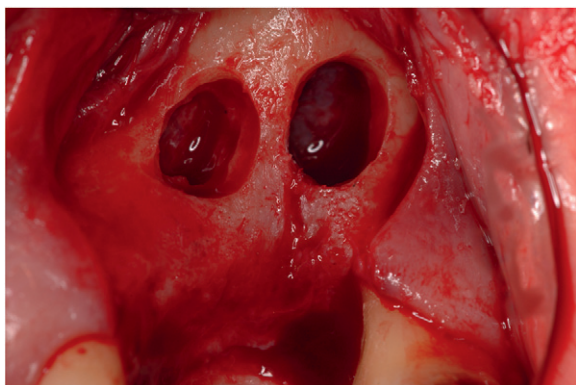
The outline of the window takes into account the septum suggested by the preoperative radiograph. This design helped to avoid perforating the membrane upon elevation.

a double window was created to avoid a Schneiderian membrane tear (Figs. 3 and 4). The elevation of the Schneiderian membrane was accomplished by initially exposing and mobilizing the membrane using the piezoelectric handpiece followed by hand instrumentation to further elevate the membrane along the medial wall of the sinus. When arterial branches of the posterior superior alveolar artery were encountered, the piezoelectric handpiece was used to isolate them and facilitate their elevation, avoiding laceration. Underwood septa were noted by direct visualization after the membrane was elevated, and the sinuses were grafted with mineralized freeze-dried bone allograft. In instances where there was a perforation/tear, a repair was performed by extending the window and covering the tear with a bioabsorbable collagen membrane prior to filling

§ Piezotome, Acteon North America, Mt. Laurel, NJ.

**Figure 3.**

Preoperative radiograph suggesting a large sinus septa.

**Figure 4.**

A double window preparation using the piezoelectric handpiece to gain better access to the membrane.

the sinus with the allograft. Tears and perforations were determined by direct visualization and the valsalva maneuver. The lateral window and graft were covered by a collagen membrane, and the flap was secured using a monofilament suture with primary closure.

RESULTS

Zero perforations of the Schneiderian membrane occurred during the preparation of the initial lateral antrostomies, whereas two perforations were noted during subsequent membrane elevations. In both instances, membrane perforations were associated with sinus septa and occurred during elevation with hand instrumentation. Overall, 17 septa were noted for a prevalence of 30%. Although arterial branches of the posterior superior alveolar artery were encountered in 35 sinuses, there were zero instances of arterial laceration. Other than sinus membrane perforations, no other complications were encountered.

DISCUSSION

The lateral window approach to maxillary sinus augmentation is a well-accepted treatment option in implant dentistry.¹⁷⁻¹⁹ With traditional techniques, the most commonly reported intraoperative complication with a lateral window approach to sinus elevation has been the perforation of the Schneiderian membrane.^{12,13} This complication is noteworthy because excessively large perforations may necessitate the abortion of the procedure, cause a delay in treatment,^{14,20} or necessitate an additional treatment associated with direct communication into the sinus. In the event that Schneiderian membrane perforations may be repaired, additional costs are necessary (e.g., incorporating the use of a guided tissue regeneration membrane for graft containment).^{14,20,21} Perforation rates associated with the lateral window approach range from 11% to 56%²²⁻²⁶ and typically occur during the preparation of the lateral sinus window or curet elevation of the Schneiderian membrane. Nkenke et al.,²⁷ in their study of endoscope use with an internal sinus lift, pointed out that micro-tears and perforations cannot be adequately determined with the valsalva maneuver, and their true determination may require the use of an endoscope.

The intimate relationship of hard to soft tissues in the maxillary sinus poses a significant dilemma. To access the pyramidal maxillary sinus for a graft addition, it is necessary to cut through hard osseous walls while avoiding laceration of the delicate Schneiderian membrane that lies just beneath the surface. Because the bony thickness of lateral maxillary sinus walls averages 0.91 mm, and the adjacent Schneiderian membrane averages 0.15 mm in thickness, the traditional use of high-speed rotating instruments for the preparation of lateral sinus antrostomies requires exacting attention to detail.²⁸ Validation of this statement is suggested by the 20% to 30% prevalence of Schneiderian membrane perforations that was reported when sharp high-speed rotating instruments were used in the preparation of lateral sinus windows.²⁹ Because piezoelectric surgery does not cut soft tissues, it stands to reason that proper piezoelectric use in the preparation of lateral sinus antrostomies would reduce the risk of Schneiderian membrane perforation.³⁰

The piezoelectric surgery unit used in this retrospective case series differed from that originally reported in prior studies.^{15,16,29,30} The unit in the present study operated at a frequency of 28 to 36 kHz with a tip amplitude that was modulated, producing microvibrations that cut bone while leaving soft tissue intact. It is possible that the advantages of the unit used in the present study, or even the one used by Vercellotti,³⁰ may be related to a factor other than

its piezoelectric effects. The only prospective controlled trial by Barone et al.²⁹ demonstrated no statistical significance in the rate of perforations between the use of the piezoelectric lateral window approach and rotary instrument preparation. Without a prospective trial that compares the current unit to a conventional approach, one can only speculate why the complication rate was so low or if, indeed, this piezoelectric unit reduces complications. However, it is the experience of the surgeons (NJT and PSR) from this case series that the piezoelectric unit simplified lateral window preparation and sinus lift treatment. Furthermore, this retrospective case series represents outcomes during the learning-curve phase with this technology, which increased the difficulty of achieving good results.

This case series resulted in no perforations of the Schneiderian membrane during the initial piezoelectric antrostomy preparation. However, there was an overall 3.6% perforation rate when factoring in the hand instrumentation. This compares favorably to both the more traditional lateral window approach where an 11% to 56% perforation rate was reported in the literature^{7,8} and to other reports^{15,16} that used different piezoelectric units. These results suggest that the ability of these units to cut bone while avoiding soft tissue injury cannot be completely discounted in reducing complications.

An additional indication that the piezoelectric unit was protective of soft tissues was the lack of arterial lacerations that occurred in this retrospective case series. Although intraosseous arterial branches were found in 100% of cadaver specimens,¹⁰ arterial branches were encountered in 62% of the lateral antrostomies in this case series. The discrepancy in the prevalence of arterial encounters in this study and prior anatomic studies of the maxillary sinus might be explained by the average location of the intraosseous arterial branch, which ranges from 16 to 19 mm from the alveolar crest.^{10,31} Therefore, if the superior aspect of the lateral antrostomy is <16 mm from the alveolar crest, there might be a chance that the artery will not be encountered. Although no arteries were transected or lacerated during this study, encountering them added time to the procedure due to the need to carefully manage them (Figs. 5 and 6).

Once the Schneiderian membrane is accessed, it must be carefully elevated to a level equal to or greater than the superior aspect of the lateral antrostomy.³² With traditional techniques, hand instruments such as curets are used to separate the Schneiderian membrane from the walls of the sinus.³³ This is a delicate procedure that often results in membrane perforation. In fact, a recent study¹⁶ evaluating 100 piezosurgical sinus lifts reported that all membrane perforations occurred during elevation of the membrane from the internal sinus walls. In the present study of 56 open sinus lifts, the two perforations that occurred during

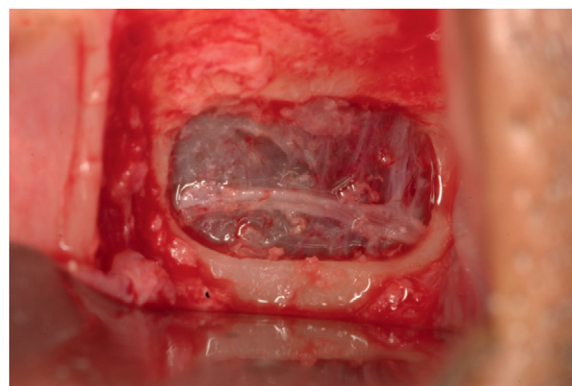


Figure 5.

Intraosseous branch of the posterior superior alveolar artery and the infraorbital artery.

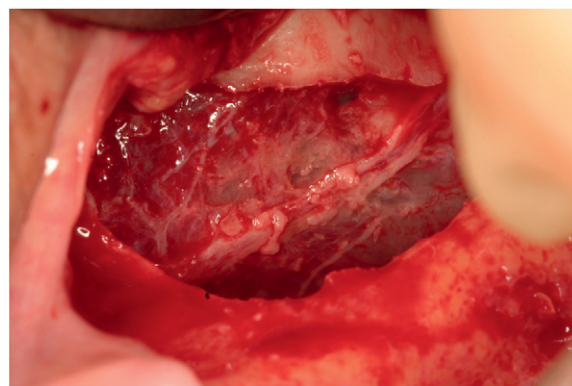


Figure 6.

Sinus membrane was carefully lifted leaving the artery intact.

membrane elevation were associated with hand instrumentation. In both instances, sinus septa were present, and using hand instrumentation to try to negotiate this anatomic obstacle was not possible. The perforations/tears were repaired by extending the window and applying a bioabsorbable collagen membrane to occlude the defect and contain the bone-replacement graft material.

CONCLUSIONS

This retrospective case series from clinical private practices confirmed that a lateral window approach to sinus elevation incorporating piezoelectric technology in conjunction with hand instrumentation was an effective means to achieve sinus elevation while minimizing the potential for intraoperative complications. Further prospective and randomized controlled studies are warranted to qualify the observations noted in this retrospective case series.

ACKNOWLEDGMENTS

Dr. Rosen is a consultant for Acteon North America, Mt. Laurel, New Jersey. Drs. Toscano and Holtzclaw report no conflicts of interest related to this case series.

REFERENCES

1. Zijdeveld SA, van den Bergh JP, Schulten EA, ten Bruggenkate CM. Anatomical and surgical findings and complications in 100 consecutive maxillary sinus floor elevation procedures. *J Oral Maxillofac Surg* 2008;66:1426-1438.
2. Van den Bergh JP, ten Bruggenkate CM, Disch FJ, Tuinzing DB. Anatomical aspects of sinus floor elevations. *Clin Oral Implants Res* 2000;11:256-265.
3. Sharan A, Madjar D. Maxillary sinus pneumatization following extractions: A radiographic study. *Int J Oral Maxillofac Implants* 2008;23:48-56.
4. Tatum H Jr. Maxillary and sinus implant reconstructions. *Dent Clin North Am* 1986;30:207-229.
5. Garg AK, Quiñones CR. Augmentation of the maxillary sinus: A surgical technique. *Pract Periodontics Aesthet Dent* 1997;9:211-219.
6. Boyne PJ, James RA. Grafting of the maxillary sinus floor with autogenous marrow and bone. *J Oral Surg* 1980;38:613-616.
7. Wallace SS, Froum SJ. Effect of maxillary sinus augmentation on the survival of endosseous dental implants. A systematic review. *Ann Periodontol* 2003;8:328-343.
8. Schwartz-Arad D, Herzberg R, Dolev E. The prevalence of surgical complications of the sinus graft procedure and their impact on implant survival. *J Periodontol* 2004;75:511-516.
9. Vercellotti T. Technological characteristics and clinical indications of piezoelectric bone surgery. *Minerva Stomatol* 2004;53:207-214.
10. Solar P, Geyerhofer U, Traxler H, Windisch A, Ulm C, Watzek G. Blood supply to the maxillary sinus relevant to sinus floor elevation procedures. *Clin Oral Implants Res* 1999;10:34-44.
11. Schlee M, Steigmann M, Bratu E, Garg AK. Piezosurgery: Basics and possibilities. *Implant Dent* 2006;15:334-340.
12. Barone A, Santini S, Sbordone L, Crespi R, Covani U. A clinical study of the outcomes and complications associated with maxillary sinus augmentation. *Int J Oral Maxillofac Implants* 2006;21:81-85.
13. Becker ST, Terheyden H, Steinriede A, Behrens E, Springer I, Wiltfang J. Prospective observation of 41 perforations of the Schneiderian membrane during sinus floor elevation. *Clin Oral Implants Res* 2008;19:1285-1289.
14. Pikos MA. Maxillary sinus membrane repair: Update on technique for large and complete perforations. *Implant Dent* 2008;17:24-31.
15. Blus C, Szmuckler-Moncler S, Salama M, Salama H, Garber D. Sinus bone grafting procedures using ultrasonic bone surgery: 5-year experience. *Int J Periodontics Restorative Dent* 2008;28:221-229.
16. Wallace SS, Mazar Z, Froum SJ, Cho SC, Tarnow DP. Schneiderian membrane perforation rate during sinus elevation using piezosurgery: Clinical results of 100 consecutive cases. *Int J Periodontics Restorative Dent* 2007;27:413-419.
17. Aghaloo TL, Moy PK. Which hard tissue augmentation techniques are the most successful in furnishing bony support for implant placement? *Int J Oral Maxillofac Implants* 2007;22 Suppl:49-70.
18. Del Fabbro M, Testori T, Francetti L, Weinstein R. Systematic review of survival rates for implants placed into the grafted maxillary sinus. *Int J Periodontics Restorative Dent* 2004;24:565-577.
19. Pjetursson BE, Tan WC, Zwahlen M, Lang NP. A systematic review of the success of sinus floor elevation and survival rates of implants inserted in combination with sinus floor elevation. *J Clin Periodontol* 2008;35(Suppl. 8):216-240.
20. Testori T, Wallace SS, Del Fabbro M, et al. Repair of large sinus membrane perforations using stabilized collagen barrier membranes: Surgical techniques with histologic and radiographic evidence of success. *Int J Periodontics Restorative Dent* 2008;28:9-17.
21. Fugazzotto PA, Vlassis J. A simplified classification and repair system for sinus membrane perforations. *J Periodontol* 2003;74:1534-1541.
22. Cho SC, Wallace SS, Froum SJ, Tarnow DP. Influence of anatomy on Schneiderian membrane perforations during sinus elevation surgery: Three-dimensional analysis. *Pract Proced Aesthet Dent* 2001;13:160-163.
23. Papa F, Cortese A, Maltarello MC, Sagliocco R, Felice P, Claudio PP. Outcome of 50 consecutive sinus lift operations. *Br J Oral Maxillofac Surg* 2005;43:309-313.
24. Hallman M, Nordin T. Sinus floor augmentation with bovine hydroxyapatite mixed with fibrin glue and later placement of nonsubmerged implants: A retrospective study in 50 patients. *Int J Oral Maxillofac Implants* 2004;19:222-227.
25. Raghoobar GM, Batenburg RH, Timmenga NM, Vissink A, Reintsema H. Morbidity and complications of bone grafting of the floor of the maxillary sinus for the placement of endosseous implants. *Mund Kiefer Gesichtschir* 1999;3(Suppl. 1):S65-S69.
26. Hernández-Alfaro F, Torradeflot MM, Marti C. Prevalence and management of Schneiderian membrane perforations during sinus-lift procedures. *Clin Oral Implants Res* 2008;19:91-98.
27. Nkenke E, Schlebel A, Schultze-Mosgau S, Neukam FW, Wiltfang J. The endoscopically controlled osteotomy sinus floor elevation: A preliminary prospective study. *Int J Oral Maxillofac Implants* 2002;17:557-566.
28. Neiva RF, Gapski R, Wang HL. Morphometric analysis of implant-related anatomy in Caucasian skulls. *J Periodontol* 2004;75:1061-1067.
29. Barone A, Santini S, Marconcini S, Giacomelli L, Gherlone E, Covani U. Osteotomy and membrane elevation during the maxillary sinus augmentation procedure. A comparative study: Piezoelectric device vs. conventional rotative instrumentations. *Clin Oral Implants Res* 2008;19:511-515.
30. Vercellotti T, De Paoli S, Nevins M. The piezoelectric bony window osteotomy and sinus membrane elevation: Introduction of a new technique for simplification of the sinus augmentation procedure. *Int J Periodontics Restorative Dent* 2001;21:561-567.
31. Elian N, Wallace S, Cho SC, Jalbout ZN, Froum S. Distribution of the maxillary artery as it relates to sinus floor augmentation. *Int J Oral Maxillofac Implants* 2005;20:784-787.
32. Garg AK. Augmentation grafting of the maxillary sinus for placement of dental implants: Anatomy, physiology, and procedures. *Implant Dent* 1999;8:36-46.
33. Smiler DG. The sinus lift graft: Basic technique and variations. *Pract Periodontics Aesthet Dent* 1997;9:885-893; quiz 895.

Correspondence: Dr. Nicholas J. Toscano, 208 High Timber Court, Gaithersburg, MD 20879. E-mail: navygumdoc@aol.com.

Submitted April 4, 2009; accepted for publication July 8, 2009.