

Case Report

Speech Pattern Improvement Following Gingivectomy of Excess Palatal Tissue

Dan Holtzclaw* and Nicholas Toscano†

Background: Speech disruption secondary to excessive gingival tissue has received scant attention in periodontal literature. Although a few articles have addressed the causes of this condition, documentation and scientific explanation of treatment outcomes are virtually non-existent. This case report describes speech pattern improvements secondary to periodontal surgery and provides a concise review of linguistic and phonetic literature pertinent to the case.

Methods: A 21-year-old white female with a history of gingival abscesses secondary to excessive palatal tissue presented for treatment. Bilateral gingivectomies of palatal tissues were performed with inverse bevel incisions extending distally from teeth #5 and #12 to the maxillary tuberosities, and large wedges of epithelium/connective tissue were excised.

Results: Within the first month of the surgery, the patient noted “changes in the manner in which her tongue contacted the roof of her mouth” and “changes in her speech.” Further anecdotal investigation revealed the patient’s enunciation of sounds such as “s,” “sh,” and “k” was greatly improved following the gingivectomy procedure.

Conclusions: Palatometric research clearly demonstrates that the tongue has intimate contact with the lateral aspects of the posterior palate during speech. Gingival excess in this and other palatal locations has the potential to alter linguopalatal contact patterns and disrupt normal speech patterns. Surgical correction of this condition via excisional procedures may improve linguopalatal contact patterns which, in turn, may lead to improved patient speech. *J Periodontol* 2008;79:2006-2009.

KEY WORDS

Case report; gingiva; gingivectomy; maxilla; palate; speech-language pathology.

Reports on the disruption of standard speech patterns by gingival maladies are scarcely documented in dental literature. A limited number of articles¹⁻¹⁴ noted that conditions such as medication-induced gingival enlargement, hereditary gingival fibromatosis, pyogenic granuloma, epulis, and idiopathic gingival overgrowth all have the potential to interfere with normal speech and communication. Although this collection of case reports and case series effectively documented the occurrence and proposed treatments for gingival-induced speech disruption, a dearth of information exists in the dental literature on treatment outcomes and scientific explanations for this topic.

The aim of the present case report is to describe improvements in speech patterns that developed following a bilateral, palatal gingivectomy procedure and to provide a review of the literature that offers a scientific rationale for this treatment outcome.

CASE REPORT

In July 2007, a 21-year-old white female presented to the Department of Periodontics, Naval Branch Health Clinic, Naval Air Station, Pensacola, Florida, with a chief complaint of recurring “pain and swelling” in the left posterior palate. The patient exhibited extremely edematous and fluctuant palatal gingiva extending distally from tooth #13 to the maxillary tuberosity. The patient was treated conservatively for a diagnosed gingival abscess and was closely followed over the next 4 weeks. During this time the gingival abscess resolved uneventfully, and the patient’s palatal tissue returned to its prepathologic state.

The normal state of the patient’s palatal tissue was best described as a bilateral, developmental, mucogingival deformity with gingival excess and 7-mm pseudopockets (Fig. 1). To reduce the likelihood of the recurrence of future gingival abscesses, bilateral gingivectomies of the excess palatal tissues were performed. Inverse bevel incisions were extended distally from teeth #5 and #12 to the maxillary tuberosities,

* Department of Periodontics, Naval Hospital Pensacola, U.S. Navy, Pensacola, FL.

† Department of Periodontics, National Naval Medical Center, U.S. Navy, Bethesda, MD.

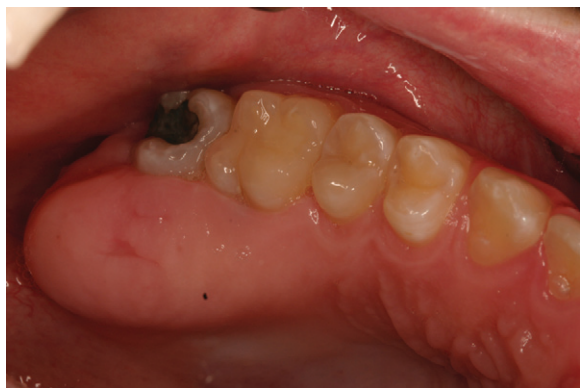

Figure 1.
Presurgical view of the right maxilla.

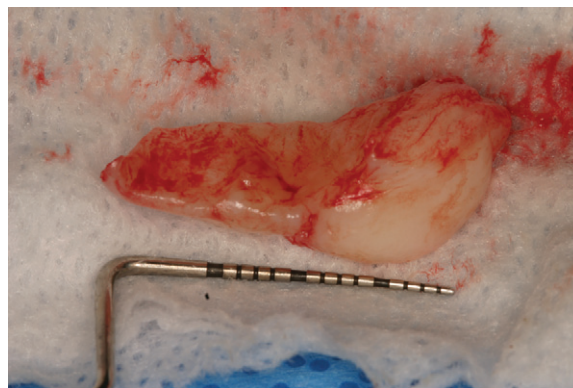


Figure 2.
Excised palatal tissue.

and large wedges of epithelium/connective tissue were excised (Fig. 2). The remaining palatal tissue was replaced with 5-0 chromic gut suture, and a periodontal dressing was applied. The patient healed uneventfully, and the surgical goals of pseudopocket elimination and improved gingival contours were achieved (Fig. 3).

During the initial post-surgical phase, the patient commented that she felt her tongue had “more space” to function within her mouth and that a number of her friends and family indicated she now “spoke more clearly.” Further anecdotal investigation via interviews with the patient’s closest acquaintances revealed that her enunciation of sounds such as “s,” “sh,” and “k” were greatly improved following the gingivectomy procedure.

DISCUSSION

Although heavily researched in relation to cleft palates and other craniofacial defects, speech pathology is a subject that has received scant attention in periodontal literature. A literature search of the MEDLINE database limited to dental journals and a combination of the terms “speech,” “speech alteration,” “gingiva,” “gingival enlargement,” and “gingivectomy” revealed only 14 articles mentioning this topic over the past 30 years.¹⁻¹⁴ The majority of these articles were case reports of pathologic conditions and none specifically focused on speech pathology.

To gain an appreciation of the relationship between speech and the periodontium, an examination of linguistic and phonetic literature is necessary. According to palatometric research by Fletcher,¹⁵ “an inherent source of physiologic variability in all speaking conditions is that movements are seldom, if ever, executed precisely the same.” This observation underscores one of the main difficulties of linguistic research: variability. Individual languages, dialects, and physiologic

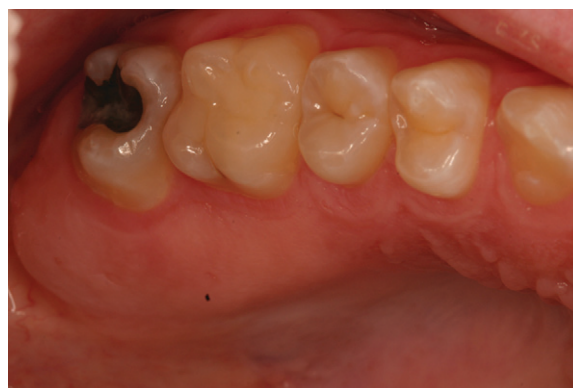

Figure 3.
Post-surgical view of the right maxilla.

challenges, such as hearing impairment or cleft palate, all produce wide ranges of variability in linguopalatal position during speech.

To assess linguopalatal contacts during speech production, speech pathologists often use palatometric tools such as the electropalatograph (EPG). EPGs consist of 62 or 96 electrodes variably arranged on thin custom acrylic palatal stents.^{16,17} Common EPG electrode configurations extend from the anterior hard palate distally to the hard/soft palate junction (Fig. 4).¹⁸ As researched by Gibbon,¹⁹ contemporary linguistic and phonetic literature noted that EPGs can be used as a clinical tool to provide real-time visual feedback for speech therapy and as a research instrument for data collection on linguopalatal articulation. Use of the EPG typically requires the user to acclimatize to the palatal prosthesis for variable time periods prior to data collection.^{20,21} Once acclimated, users are directed to enunciate specific words or sounds, and the EPG records the locations and time intervals of linguopalatal contact. The data from these procedures are

transferred to computer hard drives and processed by various linguistic software applications.²²

EPG research^{17,23} exists for a variety of spoken sounds in the English language ranging from phonemes and vowel/consonant sounds of normal speakers to abnormal articulation in subjects with cleft palates. With each study, composite EPG frames are generated and added to the database of knowledge for speech pattern recognition. Figure 5 depicts sample EPG frames for common American-English sounds.^{17,23}

Linguistics research^{24,25} has clearly demonstrated that the tongue has intimate contact with lateral portions of the posterior hard palate during normal speech production. This maneuver, termed “lateral bracing,” provides anchorage and stability to the body of the tongue and is considered essential for standard phonation.²⁴ Lateral bracing of the tongue often creates a “central palatal groove” that lacks linguopalatal contact.²⁵ The width and length of the central groove has multiple contact configurations that allow for wide variations in aperture and airflow during

sound production.²⁵ Patients with excessive palatal tissue, such as the patient in this case report, may have disruption of lateral-bracing maneuvers that results in abnormal central groove length/width and, thus, altered speech production. Correction of the palatal deformity via gingivectomy may allow the patient to attain a linguopalatal contact pattern that falls within the realm of standard palatal contact configurations. As such, changes in the patient’s speech pattern can be expected.

CONCLUSIONS

This case report anecdotally documented speech-pattern improvements following bilateral gingivectomies of excess palatal tissue and offered a scientific explanation for the treatment outcome via a concise review of linguistic and phonetic literature. To fully appreciate the ramifications of this physiologic process and develop literature-based treatment for gingival conditions that interfere with speech production, controlled scientific studies of this topic may be warranted.

ACKNOWLEDGMENTS

This article does not reflect the views or the endorsement of the United States Government, Department of Defense, Navy Medicine, or Naval Hospital Pensacola. The authors report no conflicts of interest related to this case report.

REFERENCES

1. Taylor B. Management of drug-induced gingival enlargement with orthodontic complications. *Ann R Australas Coll Dent Surg* 2000;15:150-154.
2. Palattella A, Marano G, Bollero P, Tomarelli F. Gingival overgrowth with calcium-channel blockers. Treatment options. *Minerva Stomatol* 2005;54:339-349.
3. Ong M, Chai W, Ngeow W. Recurrent gigantic pyogenic granuloma disturbing speech and mastication: A case report and literature review. *Ann Acad Med Singapore* 1998;27:258-261.
4. Oettinger-Barak O, Machtei E, Ofer B, Barak S, Peled M. Pregnancy tumor occurring twice in the same individual: Report of a case and hormone receptors study. *Quintessence Int* 2006;37:213-218.
5. Odessey E, Cohn A, Casper F, Schechter L. Hereditary gingival fibromatosis: Aggressive 2-stage surgical resection in lieu of traditional therapy. *Ann Plast Surg* 2006;57:557-560.
6. Mody R, Samdani D. Idiopathic gingival enlargement – Report of two cases. *J Pierre Fauchard Acad* 1994;8: 67-69.
7. Meraw S, Sheridan P. Medically induced gingival hyperplasia. *Mayo Clin Proc* 1998;73:1196-1199.
8. Marakoglu I, Percin E, Gursoy U, Onarlioglu B, Ergur A. Gingival fibromatosis, short stature, border-line IQ, facial dysmorphism and hepatomegaly. *Genet Couns* 2005;16:161-165.
9. Marakoglu I, Gursoy U, Cakmak H, Marakaglu H. Phenytoin-induced gingival overgrowth in un-cooperated epilepsy patients. *Yonsei Med J* 2004;45:337-340.

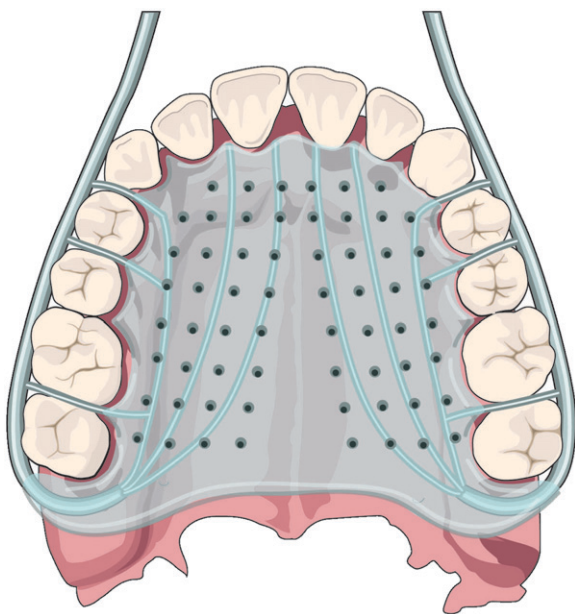


Figure 4.
Typical EPG.

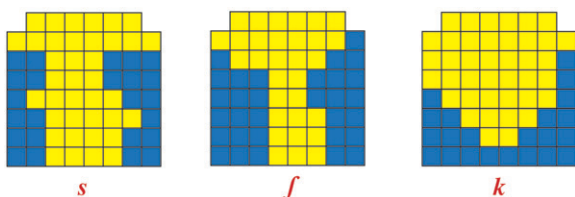


Figure 5.
Sample EPG frames. *f* = “sh” sound.

10. Khera P, Zirwas M, English J. Diffuse gingival enlargement. *J Am Acad Dermatol* 2005;52:491-499.
11. Hood K. Drug-induced gingival hyperplasia in transplant recipients. *Prog Transplant* 2002;12:17-21.
12. Halliday H, Gordon S, Bhola M. Case report: An unusually large epulis on the maxillary gingiva of a 24-year-old woman. *Gen Dent* 2007;55:232-235.
13. Hall E. Prevention and treatment considerations in patients with drug-induced gingival enlargement. *Curr Opin Periodontol* 1997;4:59-63.
14. Gagliano N, Moscheni C, Dellavia C, et al. Effect of cyclosporin A on human gingival fibroblast collagen turnover in relation to the development of gingival overgrowth: An in vitro study. *Biomed Pharmacother* 2004;58:231-238.
15. Fletcher S. Palatometric specification of stop, affricate, and sibilant sounds. *J Speech Hear Res* 1989;32:736-748.
16. Recasens D, Pallares M, Fontdevila J. Co-articulatory variability and articulatory-acoustic correlations for consonants. *Eur J Disord Commun* 1995;30:203-212.
17. Fletcher S, Newman D. [s] and [sh] as a function of linguopalatal contact place and sibilant groove width. *J Acoust Soc Am* 1991;89:850-858.
18. Hardcastle W, Gibbon F, Jones W. Visual display of tongue-palate contact: Electropalatography in the assessment and remediation of speech disorders. *Br J Disord Commun* 1991;26:41-74.
19. Gibbon F. Abnormal patterns of tongue-palate contact in the speech of individuals with cleft palate. *Clin Linguist Phon* 2004;18:285-311.
20. McAuliffe M, Ward E, Murdoch B. Tongue-to-palate contact patterns and variability of four English consonants in an /i/ vowel environment. *Logoped Phoniatr Vocol* 2001;26:165-178.
21. Gibbon F, Ellis L, Crampin L. Articulatory placement for /t/, /d/, /k/ and /g/ targets in school age children with speech disorders associated with cleft palate. *Clin Linguist Phon* 2004;18:391-404.
22. Gibbon F, Lee A, Yuen I. Tongue-palate contact during bilabials in normal speech. *Cleft Palate Craniofac J* 2007;44:87-91.
23. Dagenais P, Critz-Crosby P. Consonant lingual-palatal contacts produced by normal-hearing and hearing-impaired children. *J Speech Hear Res* 1991;34:1423-1435.
24. Gibbon F, Smeaton-Ewins P, Crampin L. Tongue-palate contact during selected vowels in children with cleft palate. *Folia Phoniatr Logop* 2005;57:181-192.
25. McLeod S, Roberts A, Sita J. Tongue/palate contact for the production of /s/ and /z/. *Clin Linguist Phon* 2006;20:51-66.

Correspondence: Dr. Dan Holtzclaw, Naval Branch Health Clinic, Naval Air Station Pensacola, 450 Turner St., Pensacola, FL 32508.

Submitted February 13, 2008; accepted for publication March 17, 2008.